

## Case presentation

# Impact of allogeneic hematopoietic stem cell transplantation on the biological parameters of immunity in patients with chronic granulomatous disease

## Reconstituția imunologică completă – factor cheie pentru evoluția pacienților cu boală granulomatoasă cronică după transplant de celule stem hematopoietice

Cristian Jinca<sup>1\*</sup>, Smaranda Arghirescu<sup>1</sup>, Mihaela Bataneant<sup>1</sup>, Mihaela Baica<sup>2</sup>, Andrada Oprisoni<sup>1</sup>, Anca Isac<sup>2</sup>, Ioana Ionita<sup>3</sup>, Malina Popa<sup>3</sup>, Valentin Ordodi<sup>1</sup>, and Margit Serban<sup>1</sup>

1. University of Medicine and Pharmacy “V.Babes” Timisoara, Department of Onco-hematology and Bone Marrow Transplantation

2. Emergency Children’s Hospital “L. Turcanu”, Timisoara, Department of Onco-hematology and Bone Marrow Transplantation

3. University of Medicine and Pharmacy “V. Babes” Timisoara, County Hospital

## Abstract

Donor derived neutrophil reconstitution, defined as the normalization of the neutrophil counts and function after allogeneic hematopoietic stem cell transplantation (HSCT), represents a prerequisite for the cure of patients with chronic granulomatous disease (CGD), expressed by a normalization of the nitroblue tetrazolium assay (NBT test), of the dihydro-rhodamine 123 (DHR) oxidation and of other confirmatory tests. These investigations together with the flowcytometric analysis of the lymphocyte subsets reconstitution at repeated post-transplant intervals predict the outcome after HSCT in these patients. Because a normalization of phagocyte activity implies a complete neutrophil engraftment with the presence of a stable and functional donor-derived neutrophil population in the transplant recipient, lineage-specific chimerism analysis represents also an important follow-up tool. All the above mentioned parameters have been investigated in two patients with CGD with a long history of life-threatening fungal and bacterial infections non-responsive to specific anti-infectious therapies, in whom the HSCT represented the only chance for cure. We showed that the hematological reconstitution in terms of absolute neutrophil count and function was very fast, within 1 month post-transplant, leading to a decisive and immediate clinical improvement of the patients, despite the delayed reconstitution of the lymphocyte subsets. The normalization of the neutrophil function tests in both patients correlated well with the achieved full donor chimerism and with the clinical outcome of these patients after the transplant. Further controlled clinical studies are warranted in order to comparatively assess the reconstitution of the lymphocyte subsets in bone marrow versus peripheral blood stem cell transplantation for CGD.

**Keywords:** Analysis of immune reconstitution, hematopoietic chimerism analysis, leukocyte oxidative burst chronic granulomatous disease, hematopoietic stem cell transplantation.

\*Corresponding author: Dr. Cristian Jinca, University of Medicine and Pharmacy „V. Babes”, III<sup>rd</sup> Clinic of Pediatrics, Center for Bone Marrow Transplantation, Str. I. Nemoianu, 2, 300011 Timișoara  
Tel: 0256-295977; Fax: 0256-295978; E-mail: cristian\_jinca@yahoo.com

## Rezumat

*Reconstituția imunologică completă după transplant alogenic de celule stem hematopoietice (TCSH), definită prin normalizarea subpopulațiilor limfocitare dar totodată și imunității nespecifice (granulocite și monocite), reprezintă o premisă pentru o reactivitate imunologică adecvată. În cazul bolii granulomatoase cronice (BGC) aceasta este exprimată și prin normalizarea testului nitroblue tetrazolium (NBT), a exploziei oxidative a neutrofilelor precum și a testului de chemiluminescență. Efectuarea acestor investigații la anumite perioade post-transplant are valoare prognostică pentru evoluția pacienților cu BGC. Deoarece normalizarea activității fagocitare după transplant implică o grefare completă a neutrofilelor cu prezența unei granulopoieze stabile derivate de la donor, chimerismul specific de linie reprezintă de asemenea o analiză importantă pentru monitorizare. Toți parametrii menționați anterior au fost investigați la doi pacienți cu BGC și cu un istoric lung de infecții fungice și bacteriene, non-responsive la terapiile specifice și pentru care TCSH a reprezentat singura șansă pentru vindecare. Normalizarea funcției neutrofilelor la ambii pacienți s-a corelat cu chimerismul complet de donor precum și cu evoluția clinică favorabilă a acestora după transplant.*

**Cuvinte cheie:** analiza reconstituției imunologice, analiza chimerismului hematopoietic, explozia oxidativă a neutrofilelor, boala granulomatoasă cronică, transplant de celule stem hematopoietice

## Introduction

Chronic granulomatous disease (CGD) is a genetically heterogeneous condition characterized by recurrent life-threatening bacterial and fungal infections and formation of granuloma. The disease develops consequently to defects in the reduced nicotinamide adenine dinucleotide phosphate (NADPH) oxidase complex, resulting in an inability to produce the superoxide anion necessary for normal destruction of bacterial and fungal microorganisms. In addition, these defects predispose to granulomatous complications and autoimmune diseases (1). Mutations in at least 5 different genes involved in the assembly and activation of the NADPH oxidase can lead to CGD. The gene encoding the enzymatic center of the NADPH oxidase, gp91phox, is located on the X chromosome and accounts for the majority of the cases. Autosomal forms occur from mutations in p47-phox p67phox, p22phox, or p40phox, the latter being only recently described. In general, gp91-phox-deficient patients are the most severely affected, whereas patients with mutations in p47-phox seem to have the best overall outcomes. Deficiency in p40phox might predispose to more gastrointestinal disease and fewer infec-

tions (2). Diagnostic tests for CGD rely on various measures of superoxide production. These include direct measurement of superoxide production, cytochrome c reduction assay, chemiluminescence, nitroblue tetrazolium (NBT) reduction test, and dihydrorhodamine 123 (DHR) oxidation test. The quantitative dihydrorhodamine 123 flow cytometry assay is today's most accurate diagnostic test for CGD (3). These neutrophil function assays are always to be completed by confirmatory tests such as immunoblot. Still there is a limitation of this technique because it cannot distinguish between the X-linked gp91phox defect and the p22phox autosomal recessive defect (4). Sequencing of the patient's phox genes to determine the exact genetic defect is most reliable but not necessary for current clinical practice (5).

Reduction in mortality and morbidity in patients with CGD is nowadays mainly attributable to improved antimicrobial prophylaxis and aggressive treatment of infections (6,7). Nevertheless, allogeneic hematopoietic stem cell transplantation (alloHSCT) remains the only way of cure (1,3,5,8). Hematologic reconstitution after alloHSCT leads to normalization of the neutrophil function along with the cure of the pre-transplant infectious complications in the case of

Table 1. Characteristics of the patients

Patient	Age	Medical history and treatment	Specific diagnostic investigations	CMV serology		EBV serology	
				Patient	Donor	Patient	Donor
Patient 1	13 years	<ul style="list-style-type: none"> <li>- repeated episodes of <b>fever</b> since the age of 3 weeks;</li> <li>- <b>cervical adenophlegmons</b> at 16 months of age, <b>hepatosplenomegaly</b>;</li> <li>- <b>several cutaneous abscedations</b> at the age of 6;</li> <li>- <b>recurrent respiratory infections, weight loss</b> since the age of 8 years;</li> <li>- <b>pneumonia of the left lower lobe with abscess formation and encapsulated pleural effusion</b>;</li> <li>- bronchoalveolar lavage (BAL) was positive for <i>Klebsiella pneumoniae</i> and <i>Candida albicans</i>;</li> <li>- at the age of 9 - <b>dorsal spine (D5-D7) osteomyelitis, pulmonary granulomata</b> as well as <b>extensive paravertebral and posterior paracostal extrapleural abscesses</b>;</li> <li>- BAL revealed abundance of <i>Aspergillus fumigatus</i></li> </ul>	<ul style="list-style-type: none"> <li>-Nitroblue tetrazolium (NBT) test - pathologic;</li> <li>-chemiluminescence absent;</li> <li>-123 - dihydro-rhodamine (123 DHR) test absent oxidant production.</li> <li>-the <b>mutation of the gene CYBB encoding the gp91<sup>phox</sup></b> on 4th exon, c.271C&gt;T, p.R91X</li> </ul>	(+)	(-)	(+)	(+)
Patient 2	7 years	<ul style="list-style-type: none"> <li>- repeated episodes of <b>bloody diarrhea, pneumonia, otitis media</b> from 2 weeks of age;</li> <li>- <b>several pulmonary, urinary tract, central venous line infections</b> with <i>E. Coli</i>, <i>Klebsiella spp.</i>, <i>Staphylococcus aureus</i>, <i>Cryptococcus neoformans</i> starting with the age of 2 years;</li> <li>-at 6 years of age pulmonary biopsy performed from a suspect lesion revealed <i>Aspergillus fumigatus</i> and <i>Serratia marcescens</i></li> </ul>	<ul style="list-style-type: none"> <li>-NBT test - pathologic;</li> <li>- <b>direct superoxide release test</b> (0,42nmol/2 million granulocytes/15 min) ;</li> <li>- the <b>phagocyte oxidase mutation gp91<sup>phox</sup></b> was also found on genetic analysis</li> </ul>	(+)	(+)	(+)	(+)

a stable donor cell engraftment. In the situation of engraftment and full donor chimerism, the full normalization of the neutrophil function is prompt in contrast with the delayed reconstitution of lymphocyte subsets. The correlation between the dynamics of the immune reconstitution and the clinical outcome of some patients with pre-transplant severe infectious complications represented the objective of our study.

## Patients and methods

We present the schedule of laboratory investigations and the outcome of 2 patients with x-linked CGD, who received an alloHSCT in the Department of Bone Marrow Transplantation of the III Clinic of Pediatrics Timisoara, using G-CSF primed peripheral blood stem

cells from a sibling brother in one case and bone marrow in the other one. The aims of this study were the assessment of the importance of hematopoietic chimerism analysis in connection with the analysis of the immune reconstitution (including neutrophil function tests) in predicting the outcome of these patients. The characteristics of the patients are shown in *Table 1*. Post-transplant chimerism analysis, flowcytometric assessment of the immune reconstitution as well as flowcytometric 123 (DHR) tests were performed after the transplantation and their results correlated with the clinical outcome.

### Patients

*Patient 1* is a 13 year-old boy presenting since the age of 3 weeks repeated episodes of fever, often of unknown origin, abscesses, phlegmons, pneumonia and osteomyelitis, requiring almost

**Table 2. Conditioning regimen, stem cell and T-cell doses, immunosuppressive therapy**

Patient	Conditioning		Immunosuppression	Graft type and content	
	Drug/dose (mg/kg/day)	Days		CD34+ (no. of cells/kg)	CD3+ (no. of cells/kg)
1	i.v.Bu/ 3.2	-9, -8, -7, -6	i.v. /oral CsA,	9.5 x 10 <sup>6</sup>	4.6 x 10 <sup>8</sup>
	i.v.Cy/50	-5, -4, -3, -2	oral MTX	PBSC	
	MabCampath/0.1	-4, -3, -2			
2	p.o.Bu/4	-9, -8, -7, -6	i.v. /oral CsA,	3.077 x 10 <sup>6</sup>	4.123 x 10 <sup>7</sup>
	i.v.Cy/50	-5, -4, -3, -2	oral MTX	bone marrow	
	MabCampath/0.1	-4, -3, -2			

Bu=busulphan, Cy=cyclophosphamide, CsA=cyclosporine A, MTX=oral methotrexate, PBSC = peripheral blood stem cells

continuous antibiotics therapy. The medical history is detailed in *Table 2*. At the age of 9 years extensive investigations including CT-scans, MRI, bone scintigraphy and a PET-CT scan were initiated in order to diagnose the septic determinations. It was then, when the cytological analysis of biological material from a thoracic collection and from bronchoalveolar lavage (BAL) revealed the presence of *Aspergillus fumigatus*. These findings prompted further specific investigations: the NBT test, 123-DHR-test, and finally the molecular genetic investigation revealing the mutation of the gene CYBB encoding the gp91<sup>phox</sup> (*Table 1*). Long-term (23 months) therapy of fungal infections with voriconazole, caspofungine, posaconazole could not control the infectious complications. HLA high-resolution molecular typing performed in our centre revealed 10/10 compatibility with the patient's brother (high resolution typing for HLA-A, B, C, DRB1, DQB1 was performed as further briefly described), making HSCT possible. At the time of the allogeneic peripheral blood stem cell transplantation (*Table 2*), performed at the age of 10 years, the patient had invasive pulmonary aspergillosis needing intensified antifungal therapy during and after the transplant.

*Patient 2* is a 7 year-old boy who presented since the age of 2 weeks repeated episodes of

bloody diarrhea, pneumonia, otitis media. At the age of 2 years, the initial suspicion of cystic fibrosis was not confirmed, the patient being transferred to our centre. Here, specific investigations towards diagnosis of CGD confirmed the disease (*Table 1*). HLA high resolution molecular typing revealed 10/10 compatibility with the patient's brother (for HLA-A, B, C, DRB1, DQB1 alleles). Long-term antifungal therapy for as long as 5 years with voriconazole, caspofungine and posaconazole, alternatively or in combination, justified the indication of transplantation of bone marrow hematopoietic stem cells from the sibling (*Table 2*).

The conditioning regimen, CD34+ and CD3+cell content of the grafts as well as the immunosuppressive prophylaxis of graft versus host disease are presented in *Table 2*.

### **Methods**

#### *HLA DNA typing*

Genotyping of HLA alleles was performed with molecular biology methods, namely the high resolution SSP-PCR (sequence-specific primer PCR) amplification technique for HLA A, B, C, DRB1, DQB1. Isolation of DNA was automated using the MagNaPure device, obtaining a DNA concentration of 53,6 ng/μL and a 260/280 fraction of 1.86. Invitrogen reagents were used for PCR

amplification and a GeneAmp 9700 thermocycler. AllSet Gold SSP Invitrogen, HLA High Resolution was used as reaction kit with a HLA SSP 96 well thermal tray. For the detection of the amplified specific product, electrophoresis in 2% agarose gel was performed (2 g agarose in 100 ml TBE 0.5X). Results were interpreted using the Unimatch Program.

#### *Cell count of the graft*

Regarding the method for CD34+ and CD3+ cell count in the graft for each donor, two tubes were prepared and processed: (1) double-staining CD34PE/CD45PerCP and (2) triple-staining CD4FITC/CD8PE/CD3PerCP. Samples were incubated with antibodies 20 min in the dark, at room temperature. The next step was the red cells lysis with BD FACS Lysing solution followed by centrifugation 5 min at 300g, then cell washing with cell-wash, resuspension and acquisition of 100.000 events. Cells were acquired on a four-color FACS Calibur flow cytometer (Becton Dickinson Biosciences) equipped with a 488 nm laser and analyzed with CellQuest 3.1 software.

Gating strategy applied for CD34+ cells detection was the two-platform ISHAGE protocol (CD34+ cells are detected based on four parameters: CD45PerCP/CD34PE/side and forward single light scatter). T-lymphocytes were determined as the percentage of cells that reacts with anti-CD3 FITC (fluorescein isothiocyanate).

#### *Post-transplant chimerism analysis*

Microsatellite analysis by PCR for hematopoietic chimerism was performed at CCRI/LabDia, Vienna, Austria, as described previously (9,10,11). Chimerism was prospectively analyzed on days: + 30, +90, +180, + 270, +365 post-transplant and yearly after, according to international guidelines (12).

#### *Analysis of the post-transplant lymphocyte subsets analysis*

Prospective immunologic reconstitution analysis of the following lymphocyte subsets was performed: CD19+, CD3+, CD3+/CD4+, CD3+/CD8+, CD3-CD16+/CD56+, CD45+RA,

CD45+RO. Timing of flow cytometric investigations: days +30, +100, +180, +270, +365, +547, +760 post-HSCT and yearly after. In order to evaluate the immune reconstitution, absolute values were compared to the mean normal absolute value of the respective age (p50) (13). Peripheral blood samples were processed using a lysis/wash technique. Briefly, whole blood was incubated with antibodies at room temperature in the dark for 15 min followed by a lysing step with BD-FACS Lysing Solution (Becton Dickinson) for 15 min in the dark and a washing step using BD-CellWash (Becton Dickinson). Cells were resuspended in BDCellWash and acquired on a BD-FACSCalibur flow cytometer.

Antibody panels utilized: CD3FITC/CD16+56PE/CD45PerCP/CD19APC; CD45RA FITC/CD45RO PE/CD3PerCP/CD4APC; CD45RA FITC/CD45ROPE/CD3PerCP/CD8APC. T, B and NK cells were analyzed and expressed as percentages from lymphocytes and then calculated in absolute number from WBC value (WBC was measured on a hemocytometer). Data analysis protocol included also naive and memory T lymphocytes.

#### *Quantitative assessment of leukocyte oxidative burst*

Heparinized peripheral blood samples were analyzed using the PHAGOBURST kit (Becton Dickinson, cat .no. 341058). This test kit allows the quantitative determination of the leukocyte oxidative burst. It contains unlabelled opsonized bacteria (*E. coli*) as particulate stimulus, the protein kinase C ligand phorbol 12-myristate 13-acetate (PMA) as high stimulus and the chemotactic peptide N-formyl-MetLeuPhe (fMLP) as low physiological stimulus. Whole blood was incubated with various stimuli at 37°C; a sample without stimulus served as negative background control. Upon stimulation, granulocytes and monocytes produce reactive oxygen metabolites. This process is monitored by the addition and oxidation of DHR 123. The percentages of cells having produced reactive oxygen radicals were analyzed as well as their

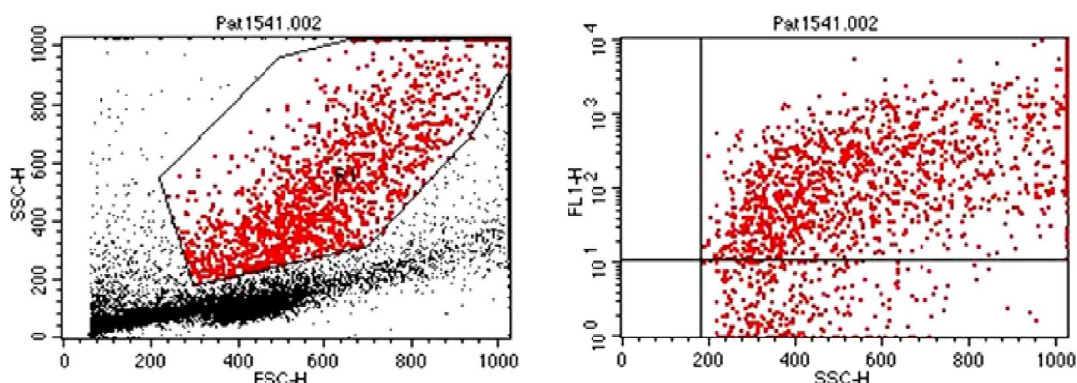


Figure 1. Oxidative burst test at 9 months post-HSCT showing 84% of normal functioning granulocytes

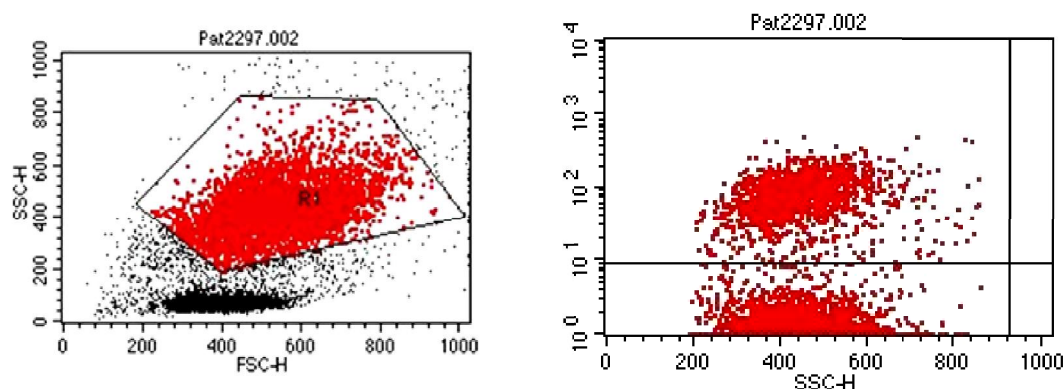


Figure 2. Oxidative burst test at 15 months post-HSCT showing 93% normal functioning granulocytes

mean fluorescence intensity (enzymatic activity) by flow cytometry using a BD FACS Calibur.

## Results

For patient 1, engraftment of neutrophils (defined as absolute neutrophil counts  $> 500/\mu\text{L}$  for 3 consecutive days) occurred on day +13 whereas for platelets (PLT) defined as PLT count  $> 20,000/\mu\text{L}$  on day +17. Lineage-specific chimerism analysis for patient 1 is presented in Figure 3. At 1 month after the transplant, granulocytes in the recipient were 96% of donor origin as well as monocytes, CD8<sup>+</sup> lymphocytes and NK cells. CD4<sup>+</sup> lymphocytes were 85% of donor origin. All leukocyte lineages progressed towards a full donor chimerism. At day +25 he presented acute graft-versus-host disease of the skin, grade II, which responded well to short course metil-

prednisolone. Superoxide anion ( $\text{O}_2^-$ ) release, measured by a validated method of the cytochrome c reduction assay at 2 months after the transplant, revealed 41.38 nmol/2 million granulocytes/15 minutes superoxide release, a good result, which correlated well with the chimerism analysis. Post-transplant therapy consisted of immunosuppression with CsA (cyclosporine A) which was tapered after 6 months and short course methotrexate. Antifungal therapy throughout the early post-transplant period consisted of high-dose Amphotericin B and was continued up to 18 months post-transplant with posaconazole and periodical combination therapy of voriconazole and caspofungine. The clinical outcome was consistent with the recovery of granulocyte function. X-ray performed at 9 months post-transplant showed a almost complete resolution of the pulmonary findings. Also, flow cytometry assess-

ment of leukocyte oxidative burst performed at 9 months post-transplant revealed 84% oxidative cells at stimulation with *E. coli* and 83 % oxidative cells at stimulation with PMA. A repeated assay at 15 months post-transplant showed a clear improvement, with 93% of phagocytosing granulocytes at stimulation with *E. coli* (Figures 1, 2).

Bronchoalveolar lavage performed at the same time revealed the absence of *Aspergillus* hyphae. Follow-up, this time non-lineage-specific, from whole blood at 3 years after the transplant revealed 97% donor cells and 3 % recipient cells in peripheral blood. These findings were consistent with the complete resolution of granulomatous and of fungal pulmonary findings on the thorax CT scan, except for fibrous sequelae, bronchiectasis and pachypleuritis. Regarding the immune reconstitution of lymphocyte subsets, there was a gradual increase of CD19+ B lymphocytes which remained below the cut-off 10<sup>th</sup> percentile value for age for over 1 year post-transplant (Figure 5). The CD4+ cell compartment normalized also towards 2 years post-transplant (Figure 5). CD8+ T cells reached the inferior normal limit at the 10<sup>th</sup> percentile value for age (p10) at around 1 years post-transplant and gradually increased thereafter towards the p50 value for age, whereas the NK cells recovered up to the p10 value around 270 days post-HSCT, decreased at 1 year and then presented a plateau at the 25<sup>th</sup> percentile value for age for another year and decreased at the p10 at the 3 years post-transplant analysis (Figure 5). At present, 3

years after his transplantation, the patient is in a very good clinical condition, goes to school and enjoys his childhood.

*Patient 2* presented neutrophil engraftment on day +15 and platelet engraftment on day +17. Chimerism analysis for this patient showed 98% donor cells (full donor chimerism) at day +90 post-HSCT.

Post-transplant therapy consisted of immunosuppression with CsA (cyclosporine A), which began to be tapered after 3 months, and short course methotrexate. Antifungal therapy was performed throughout the early post-transplant period with a combination of voriconazole and caspofungine and continued after engraftment with voriconazole alone and after 3 months with posaconazole. A thorax CT scan performed at 3 months after the transplant revealed a marked improvement with resolution of the majority of the pulmonary lesions. Flow cytometry assessment of leukocyte oxidative burst performed for patient 2 at 1 month post-transplant revealed 97 % oxidative cells at stimulation with *E. coli* and 97 % oxidative cells at stimulation with PMA (Figure 4).

The reconstitution analysis of the B-lymphocyte subset showed almost absent B cells at 1 month post-transplant but showing much improvement on day +100. Both, the CD3+CD4+ and the CD3+CD8+ compartment presented very low absolute counts even at 3 months after the HSCT. NK cells (CD3-CD16+CD56+) were within normal limits already at 1 months post-HSCT (Figure 6). The patient is now at 4 months post-HSCT, having a very good clinical status but continuing acyclovir prophylaxis due to very low CD4+ counts.

## Discussion

Although a rare disease, several reports in literature have shown especially in the last years that CGD can be cured by alloHSCT from sibling donors (14,15,16) and even from HLA matched unrelated donors (17). Cure by HSCT is associated in the majority of cases

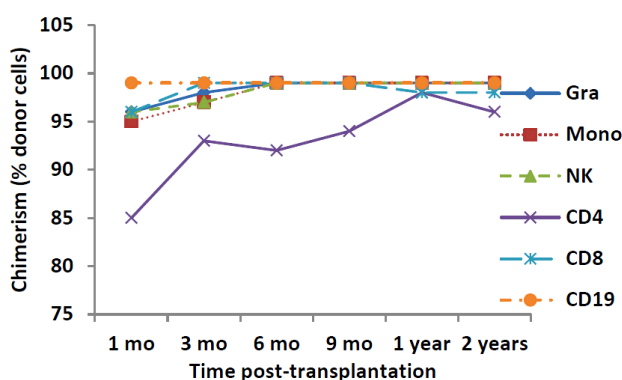
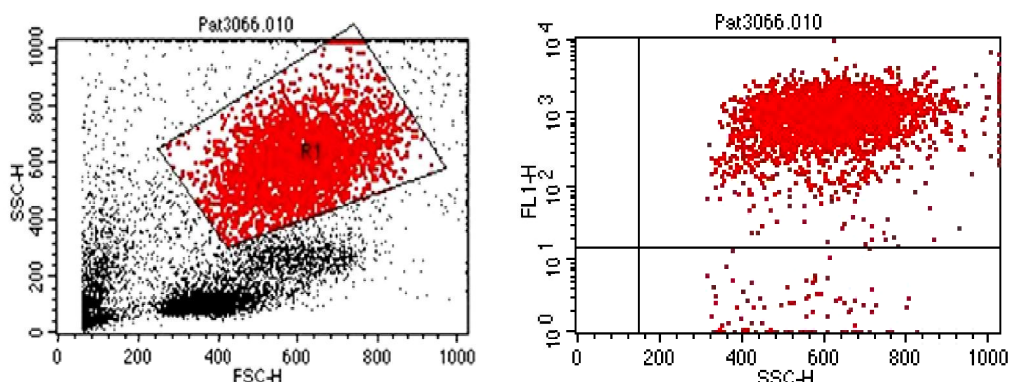


Figure 3. Patient 1 - lineage specific chimerism (STR-PCR)





**Figure 4. Oxidative burst test for patient 2 at day +30 showing 97% of normal functioning granulocytes**

with an improved quality of life as compared to patients without a transplant receiving ongoing prophylaxis with a lifelong risk of infections and nutritional problems (18,19). Even though successful alloHSCT is followed by a rapid hematopoietic reconstitution, recovery of the immune system has been shown to depend on several factors including post-transplant hematopoietic chimerism and immunosuppression (20). Both of our patients presented >90% donor chimerism at day+90 post-transplant in all cell lineages, with neutrophils as the first cell compartment to achieve full donor chimerism, and this pattern correlated well with the fast engraftment of neutrophils (both patients received myeloablative conditioning regimens), with the normalization of the oxidative burst and improvement of their clinical status. Similarly to data reported in literature, a prompt clinical improvement was obtained with clear evidence of imagistic improvement (thorax CT-scans performed starting 1 month after the transplant showing regression of pulmonary aspergillosis), even despite the complete reconstitution of the lymphocyte subsets (1,14,19).

Patient 2 presented a normal oxidative burst already at day+30 and a good clinical improvement. Chimerism analysis performed on day +90 revealed 98% donor chimerism confirming the predictive value of this analysis when correlated with the other investigations. Since CGD is an inherited phagocyte disorder,

not affecting the B- and T-cell compartment, lineage-specific chimerism for the neutrophil cell compartment could be informative enough, confirming the donor origin of phagocytosing neutrophils; still, complete serial assessment of all cell-lineages is of utmost importance for the prediction of the transplant outcome as shown in literature (10,11,21). In the majority of the cases transplanted worldwide, bone marrow was used instead of peripheral blood stem cell grafts in order to reduce the risk of GvHD. However it has been shown that earlier engraftment is achieved with PBSC grafts (22). We used two types of grafts respectively but in our cases no differences in time to neutrophil and platelet engraftment were found. However there were great differences in immune recovery of lymphocyte subsets as shown in *Figures 5 and 6*. There are host-specific and regimen-specific factors impacting on the reconstitution of the lymphocyte subsets: intensity of the conditioning regimen, stem cell source, recipient age, dose of mature cells contained in the graft and the presence or absence of GvHD. Because the standard procedure used worldwide by now suggests the use of myeloablative conditioning regimens, the immune regeneration relies predominantly on the homeostatic peripheral expansion and in a less extent on the thymus-dependent immune reconstitution due to drug-induced damage to the thymus, affecting CD4+ and CD8+ lymphocytes. This pattern is associ-



ated with inverted CD4/CD8 ratios and impaired immune function for as long as over 2 years after HSCT (23). Interestingly though, whereas the CD3+ T cells show a very slow recovery in the patient receiving bone marrow compared to the patient receiving PBSC, especially for the T helper cells, his CD19+ B cells and NK cells had a superior representation at day +30 and day +90 as compared to the patient transplanted with PBSC, consistent with the findings of some investigators (25). In contrast, other data supports evidence that the NK compartment presents similar reconstitution patterns

in both types of graft sources (22). It has been shown that rapid reconstitution of NK cells provides clear evidence of the vitality of lymphoid stem cells in the setting of alloHSCT after myeloablative conditioning regimens (23,24). In our patient transplanted with bone marrow, the normal values of the NK cells at day +30 could be considered as predictable for a favorable outcome of the transplant but they did not enhance the reconstitution of the reconstitution of the lymphoid compartment. The lack of viral complications could probably be also attributable to the post-transplant acyclovir prophylaxis

which was performed in both patients until the CD4+ count reached a stable value of 400/ $\mu$ L, explaining the need for analysis by flow cytometry at regular intervals after the transplant.

Our data suggests that there is a fast recovery of the neutrophil number and function after the alloHSCT leading to a prompt improvement of the clinical status of the patients despite the delayed lymphocyte reconstitution. Comparative data in literature regarding the lymphocyte reconstitution after transplantation using the two stem cell sources for patients with CGD is scarce, representing an interesting subject for further controlled studies.

Thus, chimerism analysis after alloHSCT, as well as flow cytometry analysis of the immune reconstitution, are diagnostic tools of utmost importance in the follow-up of patients with CGD undergoing alloHSCT.

We also strongly believe that alloHSCT could be a desirable treatment strategy for attempting the cure in young patients with CGD even before life-threatening invasive fungal infections and chronic inflammation induce end-organ damage, increasing the risk of transplant –related morbidity and mortality. Therefore patients with suspi-

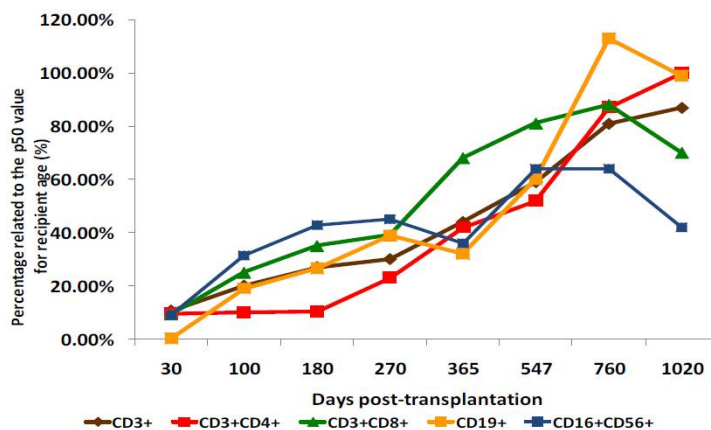


Figure 5. Reconstitution of lymphocyte subsets in patient 1

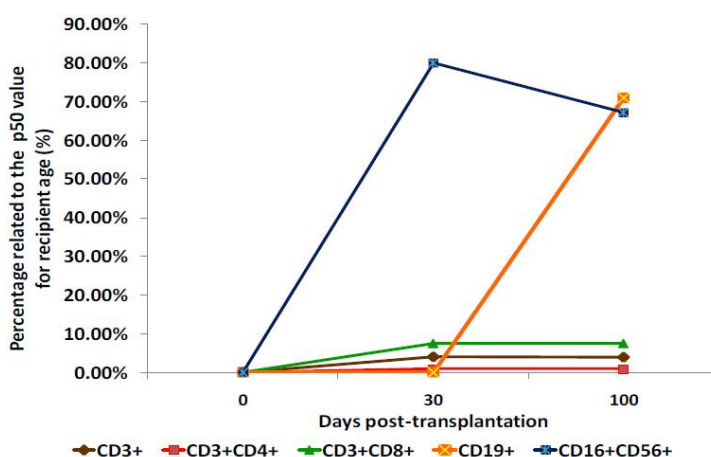


Figure 6. Reconstitution of lymphocyte subsets in patient 2

cion of CDG should be diagnosed and transplanted as early as possible in the course of the disease in the case that they have a matched sibling donor.

## Acknowledgements

We would like to express herewith our full gratitude to Prof. Dr. H. Gadner from the St. Anna Children's Hospital Vienna for his generous and essential help through all these years and to Prof. Dr. Th. Lion from CCRI/LabDia Vienna for his outstanding support with the molecular genetics investigations. We would also like to acknowledge hereby Prof. Dr. L. Marodi (Debrecen) for helping us with genetic investigations. They are significantly contributing to the quality of the transplant activity in our center.

Disclosure statement on conflict of interest. No actual conflict of interest exists among the authors of this study nor is any future conflict of interest foreseen. No special funds have been raised for the preparation of this retrospective study.

## Abbreviations

alloHSCT – allogeneic hematopoietic stem cell transplantation;  
BAL – bronchoalveolar lavage;  
Bu = busulphan,  
CGD – chronic granulomatous disease;  
CsA – cyclosporine A;  
CsA = cyclosporine A,  
CT- computed tomography,  
Cy = cyclophosphamide,  
DHR – dihydrorhodamine;  
fMLP - N-formyl-MetLeuPhe;  
G-CSF – granulocyte colony stimulating factor;  
GRA - granulocytes;  
GvHD – graft-versus-host disease FACS – fluorescence activated cell sorting;  
HLA – human leukocyte antigene;  
MONO - monocytes;  
MRI – magnetic resonance imaging;  
NADPH - nicotinamide adenine dinucleotide phosphate;

NBT - nitroblue tetrazolium;  
NK –natural killer cells  
PET-CT positron emission tomography;  
PMA - phorbol 12-myristate 13-acetate;

## References

1. Kang EM, Marciano BE, DeRavin S, Zarembler KA, Holland SM, Malech HL. Chronic granulomatous disease: Overview and hematopoietic stem cell transplantation. *J Allergy Clin Immunol* 2011;127(6):1319-26; Epub 2011 Apr 17.
2. Matute JD, Arias AA, Wright NA, Wrobel I, Waterhouse CC, Li XJ, et al. A new genetic subgroup of chronic granulomatous disease with autosomal recessive mutations in p40 phox and selective defects in neutrophil NADPH oxidase activity. *Blood* 2009;114:3309-3315
3. Seger RA. Modern management of chronic granulomatous disease. *Br J Haematol* 2008; 140: 255–266
4. Segal BH, Leto TL, Gallin JI, Malech HL, Holland SM. Genetic, biochemical, and clinical features of chronic granulomatous disease. *Medicine* 2000;79(3):170
5. Rosenzweig SD, Holland SM. Chronic granulomatous disease: Pathogenesis, clinical manifestations, and diagnosis. UpToDate 2011, Desktop version 19.1
6. Margolis DM, Melnick DA, Alling DW, Gallin JI. Trimethoprim-sulfamethoxazole prophylaxis in the management of chronic granulomatous disease. *J Infect Dis*. 1990;162(3):723
7. Gallin JI, Alling DW, Malech HL, Wesley R, Koziol D, Marciano B, et al. Itraconazole to prevent fungal infections in chronic granulomatous disease. *N Engl J Med*. 2003;348(24):2416
8. van den Berg JM, van Koppen E, Ahlin A, Belohradsky BH, Bernatowska E, Corbeel L, et al. Chronic Granulomatous Disease: The European Experience. *PLoS ONE* 2009;4(4): e5234
9. Breuer S, Preuner S, Fritsch G, Daxberger H, Koenig M, Poetschger U, et al. Early recipient chimerism testing in the T- and NK-cell lineages for risk assessment of graft rejection in pediatric patients undergoing allogeneic stem cell transplantation. *Leukemia* 2011 Sep, online
10. Lion T. Detection of impending graft rejection and relapse by lineage-specific chimerism analysis. *Methods Mol Med*. 2007;134:197-216
11. Lion T, Watzinger F. Chimerism analysis following nonmyeloablative stem cell transplantation. *Methods Mol Med*. 2006;125:275-95
12. Antin J, Childs R, Filipovich AH, Giral S, Mackinnon S, Spitzer T et al. Establishment of complete and mixed donor chimerism after allogeneic lymphohematopoietic transplantation: recommendations from a workshop at the 2001 Tandem Meetings. *Biol. Blood Marrow Transplant*, 2001;7:473-85
13. J.J. Van Dongen et al. Reference values for lympho-

cyte subpopulations in peripheral blood. *J. Pediatr.* 1997;130:388-93.

14. Leung T, Chik K, Li C, Shing M, Yuen PM. Bone marrow transplantation for chronic granulomatous disease: long-term follow-up and review of literature. *Bone Marrow Transplant* 1999;24: 567-70

15. Bhattacharya A, Slatter M, Curtis A, Chapman CE, Barge D, Jackson A, et al. Successful umbilical cord blood stem cell transplantation for chronic granulomatous disease. *Bone Marrow Transplant* 2003;31: 403-5

16. Seger RA, Gungor T, Belohradsky BH, Blanche S, Bordigoni P, Di Bartolomeo P, et al. Treatment of chronic granulomatous disease with myeloablative conditioning and an unmodified hemopoietic allograft: a survey of the European experience, 1985-2000. *Blood* 2002; 100:4344 – 5

17. Hobbs JR, Monteil M, McCluskey DR, Jurgens E, El Tumi M. Chronic granulomatous disease 100% corrected by displacement bone marrow transplantation from a volunteer unrelated donor. *Eur J Pediatr* 1992; 151(11): 806-10

18. Kang EM, Malech HL. Advances in treatment for chronic granulomatous disease. *Immunol Res.* 2009;43:77-84

19. Del Giudice I, Iori AP, Mengarelli A, Testi AM, Romano A, Cerretti R, et al. Allogeneic stem cell transplant from HLA identical sibling for chronic granulomatous disease and review of the literature. *Ann Hematol.*

2003;82:189-92

20. Savage WJ, Bleesing JJ, Douek D, Brown MR, Linton GM, Malech HL, et al. Lymphocyte reconstitution following non-myeloablative hematopoietic stem cell transplantation follows two patterns depending on age and donor/recipient chimerism. *Bone Marrow Transplant.* 2001;28:463-71

21. Bader P, Niethammer D, Willasch A, Kreyenberg H, T Klingebiel. How and when should we monitor chimerism after allogeneic stem cell transplantation? *Bone Marrow Transplant.* 2005;35:107-19

22. Ottinger HD, Beelen DW, Scheulen B, Schaefer UW, Grosse-Wilde H. Improved Immune Reconstitution After Allotransplantation of Peripheral Blood Stem Cells Instead of Bone Marrow. *Blood* 1996;88(7): 2775-79

23. Storek J, Dawson MA, Storer B, Stevens-Ayers T, Maloney DG, Marr KA, et al. Immune reconstitution after allogeneic marrow transplantation compared with blood stem cell transplantation. *Blood* 2001;97:3380-9

24. Anderson KC, Ritz J, Takvorian T, Coral F, Daley h, Gorgone BC, et al. Hematologic engraftment and immune reconstitution posttransplantation with anti-B1 purged autologous bone marrow. *Blood* 1987;54:131-8

25. Shenoy S, Mohanakumar T, Todd G, Westhoff W, Dunningan K, Adkins DR, et al. Immunoreconstitution following allogeneic peripheral blood stem cell transplants. *Bone Marrow Transplant.* 1999;23:335-46