

## ***Trichosporon asahii* fungaemia in an adult patient with acute lymphoblastic leukaemia and viral hepatitis C. A Case Report**

### **Fungemie cu *Trichosporon asahii* la o pacientă adultă cu leucemie acută limfoblastică și hepatită virală C. Prezentare de caz**

Annamária Földes<sup>1\*</sup>, Doina-Veronica Bilca<sup>1</sup>, Judit Beáta Köpeczi<sup>2</sup>, Erzsébet Benedek<sup>2</sup>, István Benedek<sup>2,3</sup>, Enikő Farkas<sup>1</sup>, Edit Székely<sup>1,4</sup>

1. Mureș County Emergency Hospital Clinics, Central Clinical Laboratory, Department of Microbiology;
2. Clinic of Haematology and Bone Marrow Transplantation, Târgu-Mureș;
3. U.M.Ph. Târgu-Mureș, Department of Medical Semiology;
4. U.M.Ph. Târgu-Mureș, Department of Microbiology

#### **Abstract**

*T. asahii* is an emerging fungal pathogen that causes severe invasive diseases, particularly in immunocompromised hosts. We report the case of a 45-year-old woman T.M. who was first diagnosed with non-Hodgkin's lymphoma (NHL) with B cells, but later pre-B acute lymphoblastic leukaemia (ALL) and viral hepatitis C were confirmed. After conventional cytostatic chemotherapy the patient achieved only partial haematological remission and she developed two periods of severe marrow aplasia. During the second period she became severely ill, with high fever (38-39 °C), and we isolated *T. asahii* from three sets of consecutive blood culture. The identification of the fungus was based on culture and microscopic characteristics, urease production and confirmed by using API Candida (BioMérieux) and Vitek 2 Compact System. The patient became afebrile after 12 days of antifungal therapy (6 days of fluconazole followed by voriconazole) associated with antibiotic therapy. Severe marrow aplasia persisted and her general condition deteriorated progressively. After 5 days of afebrility she developed signs of an acute abdominal syndrome and died of cardiac arrest. Invasive trichosporonosis should not be overlooked, particularly in neutropenic febrile patients with acute leukaemia; those received aggressive cytostatic and broad-spectrum antibiotic therapy. This case suggests the importance of identification and antifungal susceptibility testing of *T. asahii* for the application of an adequate treatment.

**Key words:** *Trichosporon asahii*, blood culture, severe marrow aplasia, immunodepression, voriconazole

---

\*Address for correspondence: Annamária Földes, Str. Victoriei 69/14, Baia Mare, Jud. Maramureș, 430072  
Tel.: 0751200852, E-mail:anafoldes@yahoo.com.

Address of institute: Mureș County Emergency Hospital Clinics, Central Clinical Laboratory, Department of Microbiology, Str. Gh. Marinescu nr. 50, Târgu-Mureș, Romania

## Rezumat

*Trichosporon asahii* este un fung oportunist emergent care provoacă infecții invazive severe, în special la persoane imunodeprimite. Redăm cazul pacientei T.M. în vârstă de 45 ani, diagnosticată inițial histopatologic cu limfom malign non-Hodgkin (LMNH) cu celule mari B, dar la care s-a confirmat ulterior prin imunofenotipare leucemie acută limfoblastică (LAL) pre-B. Totodată s-a identificat serologic și hepatită virală C. Postchimioterapie citostatică convențională s-a obținut doar o remisie hematologică parțială, pacienta dezvoltând două faze de aplazie medulară severă, ultima fiind acompaniată de sindrom febril (38-39°C) și de izolarea *T. asahii* din 3 seturi succesive de hemoculturi. Identificarea micromicetului s-a realizat pe baza caracterelor de cultură, microscopice, producției de urează, alături de API Candida (BioMérieux) și Vitek 2 Compact System. Pacienta a devenit afebrilă după 12 zile de terapie antifungică (fluconazol 6 zile, ulterior voriconazol) asociată cu antibioterapie cu spectru larg. Aplazia medulară severă a persistat. După 5 zile de afebrilitate, pe fondul unei stări generale alterate progresiv a dezvoltat semne de abdomen acut chirurgical și a decedat prin stop cardio-respirator. Trichosporonoză invazivă este un diagnostic ce nu trebuie omis la pacienții imunodeficientari febrili, mai ales cei cu leucemii acute și neutropenie, care au beneficiat de chimioterapie citostatică agresivă și antibioterapie cu spectru larg. Cazul prezentat sugerează importanța identificării și testării susceptibilității *in vitro* a *T. asahii* la antifungice în scopul instituirii unei conduite terapeutice adecvate.

**Cuvinte cheie:** *Trichosporon. asahii*, hemocultură, aplazie medulară severă, imunodepresie, voriconazol

## Introduction

The incidence of invasive fungal infections in immunocompromised patients, particularly those with haematological malignancies has risen over the last two decades, mainly as a result of the increased use of intensive cytotoxic therapy, allogeneic blood stem cell transplantation, immunosuppressive therapy<sup>7</sup> and broad-spectrum antibiotics. In this context, we participate in a diversification of species involved in fungaemia, with the decrease of *Candida albicans* strains and the increase of non-albicans species of *Candida* and the species of other genus: *Trichosporon*, *Cryptococcus*, *Malassezia* etc.<sup>2</sup>

Invasive trichosporonosis is an uncommon disease and it most frequently affects immunocompromised hosts<sup>21</sup>, especially those with neutropenia or marrow aplasia. The prognosis of trichosporonosis is poor and most frequently fatal.<sup>3, 7, 19</sup>

*Trichosporon* genus includes more than 25 species, but only 6 of them are recognized as potential human pathogens: *T. asahii*, *T. asteroides*, *T. cutaneum*, *T. inkin*, *T. ovoides* and *T. mucoides*.<sup>2</sup> *T. asahii* and *T. mucoides* have been isolated from a few patients with white

pie, but they are usually associated with deep-seated infections. *T. asteroides* and *T. cutaneum* seem to be linked with superficial infections, while *T. ovoides* and *T. inkin* are involved in white piedra of the scalp and pubic area, respectively.<sup>8</sup>

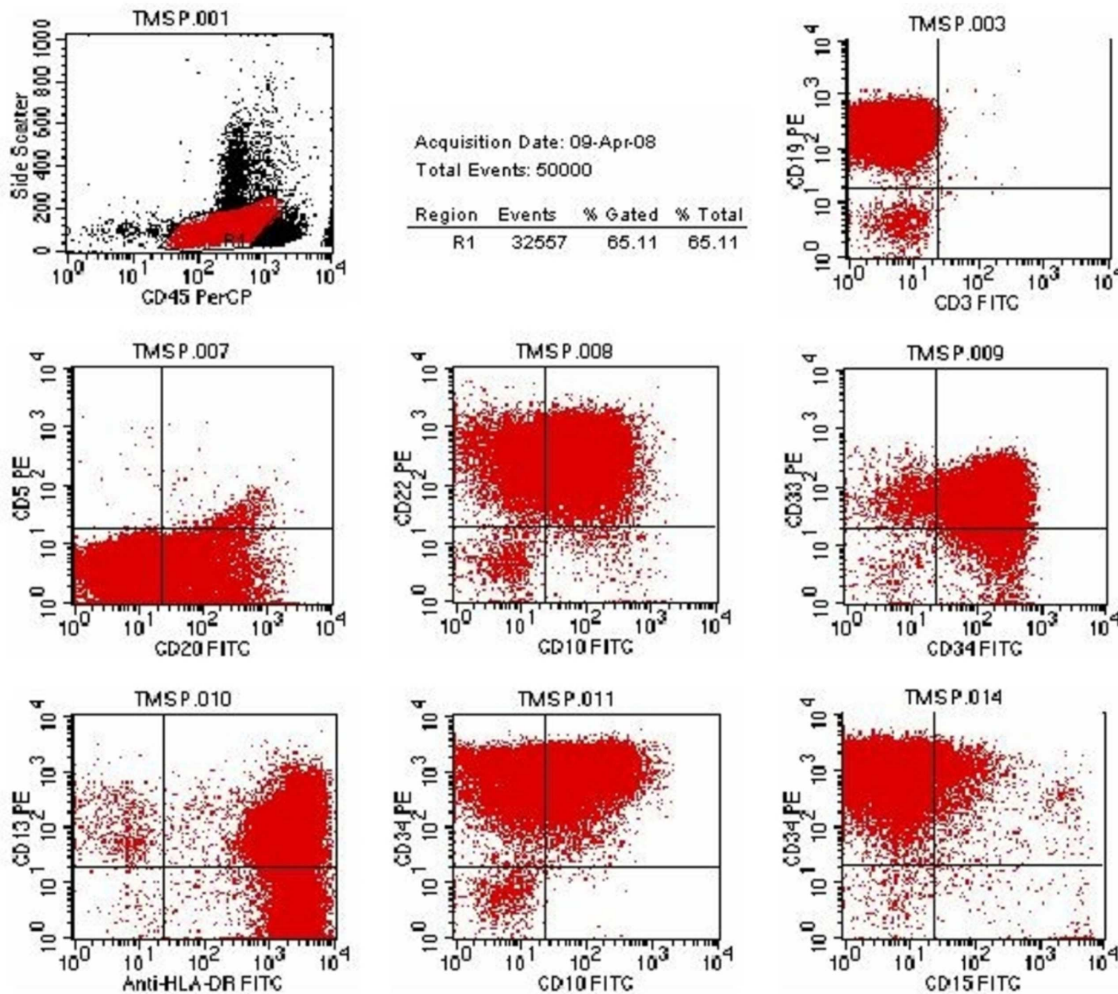
*T. asahii* is an emerging opportunistic fungal pathogen and it is included in phylum Basidiomycota, order Sporidiales. This fungal agent is commonly found in soil, water, but may also be a part of the normal human and animals flora of the oral cavity, digestive tract and skin.<sup>4,6</sup>

In immunocompetent patients *T. asahii* induces white piedra, onychomycosis, glossitis, esophagitis, meningitis, urinary tract infections etc.<sup>2, 15, 16, 17</sup>

In this paper we report the case of an adult patient with pre-B ALL and viral hepatitis C, who developed an episode of fungaemia with *T. asahii* during a period of severe marrow aplasia.

## Case Report

From the summer 2007 a 45-year-old



**Figure 1. Flow cytometry demonstrates 65,11% blasts with the following antigenic profile: CD19+, CD20+ (33%), CD22+, CD10+ (70%), CD33+ (90%), CD34+, HLA-DR+, CD13+ (61%), CD 11c + (35%).**

woman, T. M., presented a progressive tumour in the right coxofemoral region. In January 2008 an incisional biopsy of the tumour tissue was performed at the Clinic of Orthopaedy, Târgu-Mureş. The histopathologic and immunohistochemic examinations diagnosed NHL with B cells.

In January 2008 the patient was admitted to the Clinic of Haematology and Blood Marrow Transplantation at Târgu-Mureş. The movements of her right hip joint were painful and restricted. Physical examination revealed the pallor of the skin, mucosas, and a tumour of

20x30 cm in the right coxofemoral region. The size of liver and spleen was within normal limits and no lymphadenopathy was detected.

Pelvis X-ray showed osteolytic lesions in the 1/3 proximal end of the right femur. No skull modifications were observed radiologically.

Laboratory parameters, at the time of admission to hospital, were as follows: leukocyte count: 8170/ $\mu$ L (82% neutrophils, 1% eosinophils, 0% basophils, 4% monocytes, 13% lymphocytes), haemoglobin: 11g/dL, haematocrit: 34.3%, platelets: 449000/ $\mu$ L, erythrocyte

*sedimentation rate* (ESR): 110/150, fibrinogen: 682 mg%, AST: 20 U/L, ALT: 25 U/L, serum total bilirubin: 0.34 mg/dL, serum direct bilirubin: 0,11mg/dL, LDH: 276 U/L, serum iron: 11.66  $\mu$ mol/L. Bone marrow examination detected the infiltration of bone marrow with atypical cells, some of them in group disposition. Cellular series were poorly represented, but the maturation process of the cells was relatively good.

The patient received two cycles of CHOP chemotherapy: Cyclophosphamide, Fludarabine, Vincristine and Medrol for the treatment of NHL.

In March 2008 she developed a severe syndrome of hepatocytolysis (AST: 1772 U/L, ALT: 3349 U/L, serum total bilirubin: 3.95 mg/L, serum direct bilirubin: 1.59 mg/L, LDH: 1026 U/L). For this reason she was transferred to the Clinic of Infectious Diseases, Târgu-Mureș, where antibodies against hepatitis C virus (HCV) were identified by ELISA serological method. She received hydroelectrolytic treatment associated with hepatoprotector agents.

In April 2008 the patient was readmitted to the Clinic of Haematology and Blood Marrow Transplantation, Târgu-Mureș. Her general condition was severely deteriorated. She presented hepatosplenomegaly, and the hepatocytolysis syndrome was in moderate remission. The results of laboratory investigations revealed: leukocyte count: 59150/ $\mu$ L (peripheral blood smear: 65% blasts, 15% neutrophils, 0% eosinophils, 0% basophils, 1% monocytes, 19% lymphocytes), haemoglobin: 6.2 g/dL, haematocrit: 19.5%, platelets: 28000/ $\mu$ L, ESR: 50/98, fibrinogen: 174 mg%, AST: 170 U/L, ALT: 102 U/L, serum total bilirubin: 3.52 mg/L, serum direct bilirubin: 0.98 mg/L, LDH: 3171 U/L, serum iron: 48.16  $\mu$ mol/L, prothrombin index: 82%, INR: 1.11, antibodies against HCV positive (MEIA method). Immunophenotyping of peripheral blood established the diagnosis of pre-B ALL with myeloid markers (Figure 1).

Cytogenetic examination confirmed the presence of Philadelphia (Ph<sup>+</sup>) chromosome t(9;22)(9q;22q). For this reason treatment was initiated with Glivec 4x100 mg/day in association with corticotherapy. Other complex cytogenetic abnormalities such as: monosomy X, t(9;10)(p11;p11), deletion 16p- and t(2;5)(q3;q1) were demonstrated.

The conventional protocol of cytostatic chemotherapy ALL Ph<sup>+</sup> BCR/ABL was administered to the patient, but only a partial haematological remission was achieved. During the chemotherapy two periods of severe marrow aplasia appeared with leukocyte count <1000/ $\mu$ L and neutrophils count <500/ $\mu$ L. The first episode was in May 2008 (of 7 days duration) and the second was in July 2008.

Between May and July 2008 a series of bacteriological examinations were performed from the pharyngeal exudate and lingual secretion. First *Candida albicans* was identified followed by *C. krusei/ incospicua/ lambica*, and finally *C. glabrata*. In this period she received prolonged treatment with fluconazole 200 mg/day.

In July 2008 the patient was again hospitalized to the Clinic of Haematology and Blood Marrow Transplantation, Târgu-Mureș. She developed the second period of severe marrow aplasia, which was accompanied with fever (temperature 38-39°C). We isolated *T. asahii* from three sets of consecutive blood cultures (in pure culture). She received broad-spectrum antibiotic therapy (Tienam, Zyvoxid) associated with fluconazole 200mg/day in the first 6 days, followed by voriconazole. She became afebrile after 12 days of this combined treatment. The patient remained severely aplastic despite administrations of hematopoietic growth factors. Her general condition deteriorated progressively and after 5 days of afebrility presented signs of an acute abdominal syndrome. Surgical intervention was not possible because of her poor clinical condition and the laboratory parameters that had profoundly altered. Physical

examination suggested the probability of an intestinal perforation. She died of cardiac arrest.

### Microbiological investigations

Gram-stained direct smear from the blood cultures revealed yeast cells, blastoconidia and hyphae. The blood samples were cultured on routine media including sheep blood agar, Sabouraud's dextrose agar (SDA), chromogen media Candiselect 4 (BioRad) and incubated overnight at 37°C and 25°C. At both these temperatures rapidly growing colonies of yeast-like fungus were obtained in pure cultures. After 24 hours of incubation on sheep blood agar and SDA the smooth, punctiform and white coloured colonies appeared. On Candiselect 4 we observed a weak growth; the colonies were first mauve coloured, and after 48 hours became green-turquoise. The colonies grew in size progressively after 2-3 days on SDA. They became white to cream coloured with heaping at the centre. (Figure 2). With time, the centre of mature colonies became cerebriform (wrinkled) and it was surrounded by a velvety and powdery zone (Figures 3, 4). The rest of colonies remained un-pigmented.

Gram-stained smear from a 24 hours old culture illustrated true hyphae, blastoconidia, pseudohyphae and rectangular arthroconidia (Figure 5). After 48 hours later we observed a decrease in the number of blastoconidia, and 4 – 5 days later hyphae showed decreasing trend while the arthroconidia became predominant (Figures 6, 7).

API Candida (BioMérieux) identified fungus as *Trichosporon* spp. 2 with 99% confidence value. This isolate was urease positive and the germ-tube test was negative. Follow-up test, using the Vitek 2 Compact System, identified *T. asahii*.

### Discussion

*T. asahii* has emerged as a life-threatening opportunistic pathogen in immunocompromised patients, but it has also been reported to cause different types of infections in immunocompetent hosts, too.

Watson and Kallichurum reported the first case of disseminated trichosporonosis in 1970.<sup>20</sup>

Our case presents some characteristics. In the first place we report an atypical debut of ALL in an adult patient, with osteoarticular manifestations, osteolytic femoral lesions and an aleukaemic blood picture, but with elevated ESR. In the second place, co-expression of myeloid markers on pre-B lymphoblasts, the presence of Ph' chromosome and other complex cytogenetic modifications are a signal for a high risk ALL. In the third place this case is suggestive for an invasive trichosporonosis which appears during a severe marrow aplasia in a patient with ALL and viral hepatitis C.

Invasive trichosporonosis was diagnosed most frequently in patients with acute leukaemia.<sup>7</sup> Most of the infected patients had been treated with conventional cytotoxic chemotherapy, corticosteroids and broad-spectrum antibiotics.<sup>7</sup> The victim of *Trichosporon* spp. infection is the neutropenic patient, implying that neutrophils are the most important defence cells against this fungus.<sup>10</sup>

Invasive trichosporonosis was defined as "proven" when one or more of the following criteria were met:

- blood cultures yielding *Trichosporon* spp. in patients with temporally related clinical signs and symptoms of infection,
- positive cerebrospinal fluid culture results, or
- biopsy specimens that were culture positive for *Trichosporon* spp. and presented histopathologic evidence of fungal growth characterized by minimal septate hyphal branching, blastoconidia and fragmentation of the myceli-

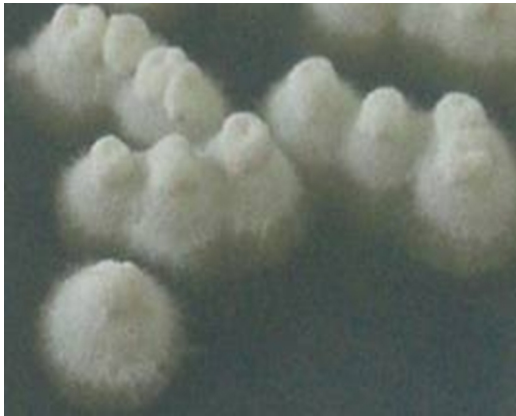

Figure 2. Appearance of colonies on SDA after 72 hours

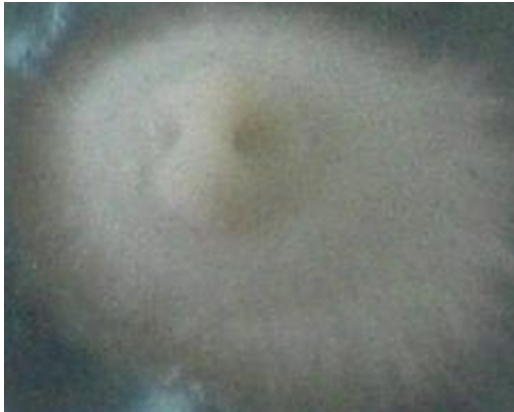

Figure 3. Morphological features of an isolate colony on SDA after 4 days



Figure 4. Morphological features of an isolate colony on SDA after 5 days

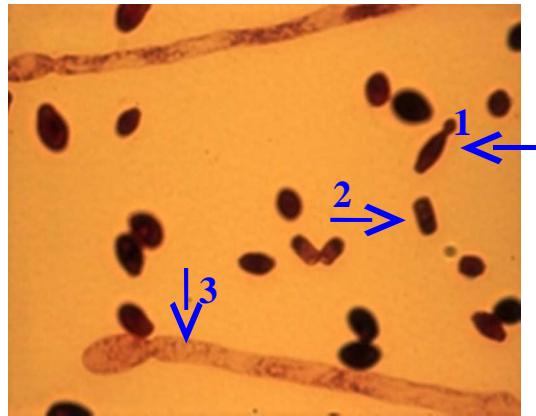


Figure 5. Gram-stained smear of 24 hours old colonies showing: 1. blastoconidia, 2. arthroconidia, 3. pseudohyphae (1000x)

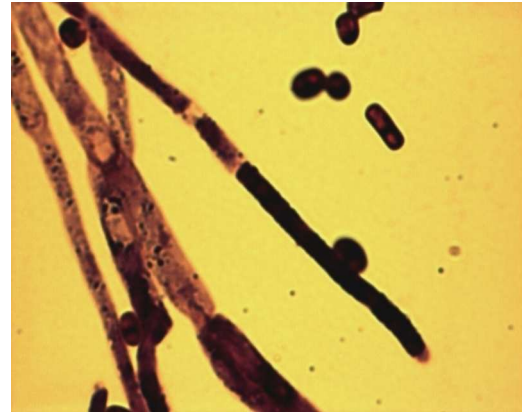


Figure 6. Gram-stained smear of 48 hours old colonies showing: septate hyphae, arthroconidia (1000x)

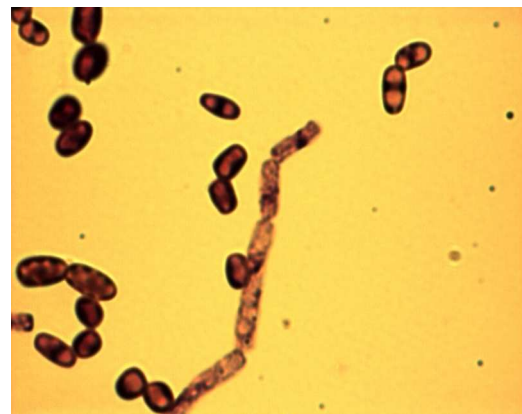

Figure 7. Gram-stained smear from 5 days old culture showing numerous arthroconidia, true hyphae that disarticulate into rectangular arthroconidia (1000x)

um in arthroconidia (definition published by the European Organization for Research and Treatment of Cancer Invasive Fungal Infection Co-operative Group EORTC/IFICG and National Institute of Allergy and Infectious Disease Mycoses Study Group NIAID/MSG)<sup>1</sup>.

In our case fever was the only sign of infection associated with fungaemia. An Italian multicenter retrospective study showed that invasive infection with *Trichosporon* spp. was confirmed by bloodcultures in 75% of patients.<sup>7</sup> In most of the cases of fungaemia, focal or disseminated invasive tissue infection was documented; less commonly fungaemia was associated only with fever, which was unresponsive to broad-spectrum antibiotics.<sup>7</sup> Invasive tissue infections were defined as focal when the involvement of a single organ site was proved and disseminated when two or more organs were involved.<sup>1</sup> In our case necroptic examination was not performed, therefore we could not exclude the involvement of different organs.

The source of human *Trichosporon* is believed to be the patient's own endogenous mycobiota. Mucosal colonisation, which may be enhanced by antibiotic therapy and subsequent seeding of the bloodstream through breaks in the integrity of the surface, is considered to be an early sequence in the pathophysiology of invasive disease.<sup>6</sup>

During the multiple hospitalizations, our patient had no central venous, gastric or vesical indwelling catheters, which could be a possible source of exogene colonization. A recent study demonstrated that only in 3% of cases the infection with *Trichosporon* spp. was related to a central venous catheter.<sup>7</sup>

In our patient we detected simultaneous *T. asahii* from bloodcultures and *C. glabrata* from the pharyngeal exudate and lingual secretion. It is important to note that this episode of fungaemia was not induced by this species of *Candida* genus. Between May and June 2008 our patient received prolonged treatment with fluconazole and this aspect suggests that this

antifungal agent did not offer protection against an invasive trichosporonosis. Kromery et al. reported nosocomial breakthrough fungaemia due to *Trichosporon* during itraconazole prophylaxis.<sup>9</sup>

The crude mortality in systemic trichosporonosis is about 80% in patients with persistent neutropenia.<sup>7,19</sup>

It is important to note that trichosporonosis may appear similar to disseminated candidiasis both in its clinical and histopathologic appearance.<sup>6</sup> We performed differential diagnosis with other genus of fungus and other species of *Trichosporon*. *T. asahii* differs from *Candida* by colonies features, producing arthroconidia, the biochimic profile and germ-tube test negative. *Geotrichum candidum* is a species with similar colony findings, which is differentiated from *Trichosporon* by morphology (it produces arthroconidia without blastoconidia) and by biochemical properties (urease production positive).

*In vitro* susceptibility findings can be a useful guide in selecting an adequate antifungal therapy for trichosporonosis. In our situation, we could not test *in vitro* susceptibility to fluconazole, voriconazole, amphotericin B, itraconazole and 5-flucytosine. Echinocandins, caspofungin, anidulafungin and FK 463 have practically no activity against *Trichosporon* isolates.<sup>5,18</sup>

After microbiological identification of fungus and consultation with relevant publications, fluconazole was replaced with voriconazole in the treatment administered to our patient. Although, in recent studies, the new triazoles: voriconazole, posaconazole and ravuconazole have displayed potent *in vitro* activity against isolates of *T. asahii* and other *Trichosporon* spp.<sup>14</sup>, but the resolution of infection in patients with neutropenia is primarily dependent on recovery from granulocytopenia.<sup>13</sup> Wolf et al. reported *Trichosporon* isolates with multi-drug resistance to amphotericin B, 5-flucytosine, fluconazole and itraconazole.<sup>22</sup>

Despite our patient became afebrile after 12 days of combined treatment, the efficacy of voriconazole must have been considered with some reservations:

- severe marrow aplasia persisted,
- in the progress of disease negative blood culture was not obtained,
- the symptoms and signs of inflammation can be minimal or even absent in patients with severe neutropenia.

The diagnosis of *Trichosporon* infections relies on clinical suspicion and microbiological confirmation.

## Conclusions

Invasive trichosporonosis should not be overlooked, particularly in neutropenic febrile patients with acute leukaemia, those received aggressive cytostatic and broad-spectrum antibiotic therapy. This case suggests the importance of identification and antifungal susceptibility testing of *T. asahii* for the application of an adequate treatment.

## References

1. Asciglu S., Rex J.H., B. de Pauw, Bennett J.E., Bille J., Crokaert F., Denning D.W., Donnelly J.P., Edwards J.E., Erjavec Z., Fiere D., Lortholary O., Maertens J., Meis J.F., Patterson T.F., Ritter J., Selleslag D., Shah P.M., Stevens D.A. and Walsh T.J. Defining opportunistic invasive fungal infections in immunocompromised patients with cancer and hematopoietic stem cell transplants: an international consensus. *Clin Infect Dis* 2002; 34: 7-14.
2. Buiuc D., Neagu M. *Tratat de microbiologie clinică*, Ediția a II-a. Editura Medicală, București, 2008, p.961-994.
3. Chowdhary A., Ahmad S., Khan Z.U., Doval D.C., Randhawa H.S. *Trichosporon asahii* as an emerging etiologic agent of disseminated trichosporonosis: A case report and an update. *Indian J Med Microbiol* 2004; 22:16-22.
4. Coman I., Mareș M. *Micologie medicală aplicată*. Editura Junimea, Iași, 2000, p.261-265
5. Espinel-Ingroff A. Comparison of in vitro activities of the new triazole SCH56592 and the echinocandins MK0991 (L-743,872) and LY303366 against opportunistic filamentous and dimorphic fungi and yeasts. *J Clin Microbiol* 1998; 36: 2950-56.
6. Ghiasian S.A., Maghsood A.H., Mirhendi S.H. Disseminated, fatal *Trichosporon asahii* infection in a bone marrow transplant recipient. *J Microbiol Immunol Infect* 2006; 39: 426-429.
7. Girmenia C., Pagano L., Martino B., D'Antonio D., Fanci R., Specchia G., Mellilo L., Buelli M., Pizzarelli G., Venditti M., Martino P. and the GIMEMA Infection Program. Invasive infections caused by *Trichosporon* species and *Geotrichum capitatum* in patients with hematological malignancies: a retrospective multicenter study from Italy and review of the literature. *J Clin Microbiol* 2005; 43: 1818-28.
8. Gueho E., Improvisi L., G.S. de Hoog, Dupont B. *Trichosporon* on humans: a practical account. *Mycoses* 1994; 37: 3-10.
9. Kromery, V., Jr., E. Oravcova, S. Spanik, M. Mrazova-Studena, J. Trupl, A. Kunova, K. Stopkova-Grey, E. Kukuckova, I. Krupova, A. Demitrovicova, and K. Kralovicova. Nosocomial breakthrough fungaemia during antifungal prophylaxis or empirical antifungal therapy in 41 cancer patients receiving antineoplastic chemotherapy: analysis of aetiology risk factors and outcome. *J Antimicrob Chemother* 1998; 41: 373-380.
10. Lyman C.A., Garret K.F., Pizzo P.A., Walsh T.J. Response of human polymorphonuclear leukocytes and monocytes to *Trichosporon beigeli*: host defense against an emerging opportunistic pathogen. *J Infect Dis* 1994; 170: 1557-65.
11. Marsh Jr. W.L., Bylund D.J., Heath V.C., Anderson M.J. Osteoarticular and pulmonary manifestations of acute leukemia. case report and review of the literature. *Cancer* 1986; 57: 385-390.
12. Mohanty P.K., Patel D.K., Majhi C.D., Nanda R., Guhathakurta S. Aleukemic acute lymphoblastic leukemia in adult presenting with rheumatic manifestations and osteolytic vertebral lesions. *J Indian Rheumatol Assoc* 2004; 12: 150-152.
13. Nakagawa T., Nakashima K., Takaiawa T. et al. *Trichosporon cutaneum (Trichosporon asahii)* infection mimicking hand eczema in a patient with leukemia. *J Am Acad Dermatol* 2000; 42: 929-931.
14. Paphitou N.I., Ostrosky-Zeichner L., Paetznick V.L., Rodriguez J.R., Chen E., Rex J.H. In vitro antifungal susceptibilities of *Trichosporon* species.



- Antimicrob Agents Chemother 2002; 46: 1144-46.
15. Rastogi V.L., Nirwan P.S. Invasive trichosporonosis due to *Trichosporon asahii* in a non-immunocompromised host: a rare case report. Indian Journal of Medical Microbiology 2007; 25(1): 59-61.
  16. Shareef B.T., Harun A., Roziawati Y., Shaiful Bahari I., Deris Z.Z., Ravichandran M. Recurrent *Trichosporon asahii* glossitis: A case report. J Contemp Dent Pract 2008; (9)3: 114-120.
  17. Sood S., Pathak D., Sharma R., Rishi S. Urinary tract infection by *Trichosporon asahii*. Indian Journal of Medical Microbiology 2006; 24(4): 294-6.
  18. Tawara S., Ikeda F., Maki K., Morishita Y., Otomo K., Teratani T., Goto M., Tomishima M., Ohki H., Yamanda A., Kawabata K., Takasugi H., Sakane K., Tanaka H., Matsumo F., Kubahara S. In vitro activities of a new lipopeptide antifungal agent, FK463, against a variety of clinically important fungi. Antimicrob Agents Chemother 2000; 44: 57-62.
  19. Walsh T.J., Groll A., Hiemenz J., Flemming R., Roilides E., Anaissie E. Infections due to emerging and uncommon medically important fungal pathogens. Clin Microbiol Infect 2004; 10: 48-66.
  20. Watson K.C., Kallichurum S. Brain abscess due to *Trichosporon cutaneum*. J Med Microbiol. 1970, 3: 191-193.
  21. Winn W. Jr., Allen S., Janda W., Koneman E., Procop G., Schreckenberger P., Woods G. Koneman's Color Atlas and Textbook and Diagnostic Microbiology – sixth edition, 2006: 21: 1223-1225.
  22. Wolf D.G., Falk R., Hacham M., Theelen B., Boekhout T., Scorzetti G., Shapiro M., Block C., Salkin I.F., Polacheck I. Multidrug-resistant *Trichosporon asahii* infection of nongranulocytopenic patients in three intensive care units. J Clin Microbiol 2001; 39: 4420-25.